



Implant-based multiplane breast augmentation—a personal surgical concept for dynamic implant–tissue interaction providing sustainable shape stability

Peter M. Vogt¹ · Marian S. Mackowski² · Khaled Dastagir¹

Received: 24 November 2020 / Accepted: 29 March 2021 / Published online: 23 April 2021
© The Author(s) 2021

Abstract

Background The aesthetic long-term stability in shape, symmetry, and natural appearance of an aesthetically augmented breast remains a constant challenge. It has become clear that the results depend strongly on the technique applied and the experience of the surgeon. An ongoing controversy concerns the positioning of the implants. Subglandular, submuscular, partial submuscular, and subfascial pockets have different tradeoffs and advantages. However, secondary deformity, unnatural feel, and appearance are not addressed uniformly. The aim of the following study was to establish a standard procedure allowing for the desired and reproducible results to provide long-term stability and aesthetic quality.

Methods The authors have developed a standardized dissection of a dynamic implant pocket. In this approach, a submuscular dissection with lower and medial release of the pectoralis muscle is combined with a wide subfascial release of the breast gland and a scoring of the deep plane of the superficial glandular fascia. In the final step, the deep layer of the glandular fascia is sutured tightly and firmly to the deep layer of the abdomino-pectoral fascia. A total of 867 patients received a 4D pocket-based breast implant by the authors. A subset of 33 patients was further analyzed for long-term results. Retrospectively, all data were analyzed from the electronic patient information system and files of patients using GraphPad 8. For comparison of multiple experimental groups, one-way ANOVA was performed where indicated.

Results The concept not only addresses the biplanar approach of submuscular implant placement (3D) but adds the 4th dimension (4D) of an aesthetically pleasing dynamic shape of the augmented breast providing long-term stability. Measurements—taken at 3 months, and 1, 2, 3, 5, and ≥ 7 years post augmentation—for SN-N, N-IMF, N-ML, and MC-N distances did not show any significant changes over time. In the patient cohort of 867 patients (1734 implants), the overall complication rate was $< 5\%$. Revisions for bleeding were below 0.5%. Shape stability was observed over 7 years in more than 95% of the patients.

Conclusions Our results indicate that our technique of multiplane breast augmentation provides long-term stability and aesthetic quality. It may solve some of the existing tradeoffs of the different methods by combining the benefits of each technique supported by an additional shaping through a controlled deep fasciotomy.

Level of evidence: Level IV, therapeutic study.

Keywords Breast augmentation · Silicone implants · Dual-plane technique · Modification · Subglandular fasciotomy · Breast fascial system · Dynamic pocket · Long-term stability

Peter M. Vogt and Marian Mackowski contributed equally to the manuscript.

✉ Peter M. Vogt
Vogt.Peter@mh-hannover.de

¹ Department of Plastic, Aesthetic, Hand and Reconstructive Surgery, Hannover Medical School, Carl-Neuberg-Strasse 1, 30625 Hannover, Germany

² Medical ONE Esthetic Clinic, Borsteler Chaussee 55, 22453 Hamburg, Germany

Introduction

Aesthetic breast augmentation remains among the top aesthetic surgical procedures and is considered to be a highly elective operation with considerable long-term liabilities for the patients. Therefore, a technique that provides highly reproducible aesthetic results at a low rate of reoperation and long-term stability of the results is warranted. The aesthetic early and long-term stability in shape, symmetry, and natural

appearance of an augmented breast has challenged plastic surgeons since the world's first augmentation by Cronin and Gerow [1]. They used a subglandular epipectoral route that remained a standard despite significant complication rates partly related to the early generation of implants themselves. In 1968 [2], subpectoral prosthesis implantation was introduced, a concept that was widely adopted by many surgeons due to several advantages such as a lower incidence of capsular contracture, better infection resistance, preservation of nipple sensation, and improved breast contour due to the fact that the implant edges are covered by the muscle. The occurring problem of lateral shift of the implants due to pectoralis muscle action was solved by muscle release from the lower medial costal and sternal origin.

Tebbetts later advocated the principle of “dual plane breast augmentation” [3]. His technique generates an altered parenchyma–muscle interface thereby minimizing typical complications such as the double bubble phenomenon. He preserved the medial and lower pectoralis muscle origin in order to avoid protrusion of the implant and symmastia. In his technique, the muscle must be divided to lower the inframammary fold.

Later as advocated by Ruth Graf [4], a purely subfascial approach was considered to provide better implant coverage than the subglandular route. At the same time, this approach avoided the dissection of the pectoralis muscle. Despite these inaugural methods, breast augmentation has been constantly challenged by the fact that predictable long-term results without capsular contracture cannot be achieved in all patients [5]. Partly this is due to the fact that, in submuscular augmentation, using the standard method an unnatural move or even frozen aspect together with muscular animations or waterfall deformity may lead to an unfavorable result [6]. We found that the mobile part of the lower breast gland and its adipose tissue contributes significantly to a natural appearance of the breast. This feature is mainly addressed in the subglandular and subfascial dissection but cannot be specifically addressed in the standard submuscular pocket dissection. We approach the interface between the gland and the pectoralis major muscle (PMM) and perform multiple incisions into the deep layer of the superficial fascia (SF). Cooper's suspensory ligaments, closely networked to the fibers and bands of the thoracic fascial system, then immediately diverge and slide apart causing firstly the enlargement of the glandular foot print and secondly deliver the required pocket for the implants, consisting of tissues with proven highest elastic modulus.

We have therefore further developed the dual-plane technique by adding a significant subfascial dissection of the mammary gland, a release of the pectoralis origin, incision of the deep fascia attached to the muscle and incisions of the deep layer of the superficial glandular fascia. Furthermore, in this technique, the definition of the lower breast pole and

inframammary fold is no longer left to natural tissue sagging alone but is controlled by an immediate release of the glandular deep fascial plane and definite anchoring of this fascial layer to the thoracoabdominal fascia.

Here we describe how the control of definite breast shape and the avoidance of unnatural animation are achieved by creation of a highly mobile implant 4D pocket that extends and stretches with the natural tissue movement along with the mobilized and loose lower muscle margin and in which the implant becomes an integral part of the breast glandular tissue.

Patients and methods

Since 2008, $N = 867$ patients received a 4D pocket–based breast implant by the authors.

The pocket consists of a submuscular plane superiorly (at or slightly above the inter nipple–areola–complex (NAC) line) and a subglandular/subfascial plane that extends down to the inframammary fold. The 4-D pocket is defined by an extra dimension in addition to the volume: the elastic movement of the implant and the gland which is accomplished by a specific dissection in the subfascial plane and additional incisions of the deep fascial plane according to the size and dimensions of the implant. Because of this 4th dimension in addition to the conventional 3 dimensions of implant insertion accompanied by elastic movement, it was called 4D pocket.

Surgical technique

The surgical procedure (also see supplemental digital content) consists of the following technical key points that are strongly related to important anatomical structures (Fig. 1.):

- The superficial glandular fascia with the superficial and deep plane
- The subglandular plane above the major pectoralis muscle (MPM) fascia
- The lower major pectoralis muscle (MPM) margin
- The sternal and lower sternocostal MPM origin
- The deep thoraco-abdominal fascia
- The submuscular plane

Technical key points are:

- The new inframammary fold is defined preoperatively according to the implant size at the patient standing upright. After standardized measurement of breast width and height, jugulum–umbilicus distance, position of the nipple, inframammary fold (IMF), and marking of the anterior axillary line, the implant will

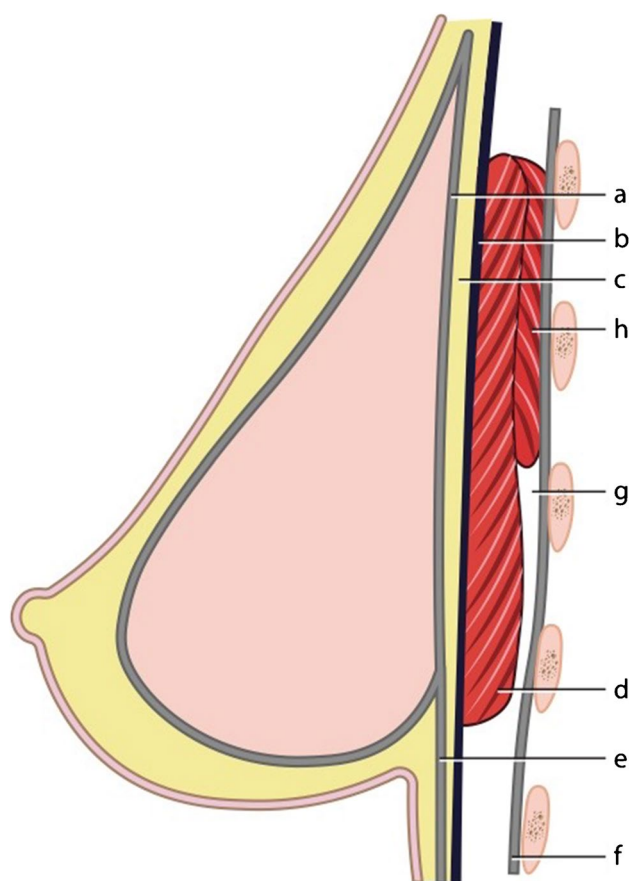


Fig. 1 a–g Anatomical structures relevant for creating a dynamic 4D pocket: the deep layer of the superficial glandular fascia (a) and the deep fascia (b). The subglandular interface above the major pectoralis muscle (c) and the lower major pectoralis muscle margin (d). The superficial fascia (e) and the thoracoabdominal deep fascia (f). The submuscular plane (g) and the minor pectoralis muscle (h)

be chosen according to the desired breast width. The implant size defines the new IMF which needs to be lowered due to the increasing nipple-crease-distance (NCD). We use a modification of Per Hedens algorithm. In case of a 425 cc implant with a 13-cm diameter (radius $r = 6.5$ cm), the formula for the new infranipple crease distance (N-ICD) calculates: $r + r/2 = 6.5 + 3.25 = 9.75$ cm.

The skin incision is then placed exactly in this fold extending symmetrically medially and laterally to the breast median. The inframammary incision is between 6 and 8 cm for three reasons:

1. In order to provide a comfortable exposure of the 4 D-lodge
2. To reduce shear forces on the implant during insertion and
3. To enable stable suturing of the fascial sutures.

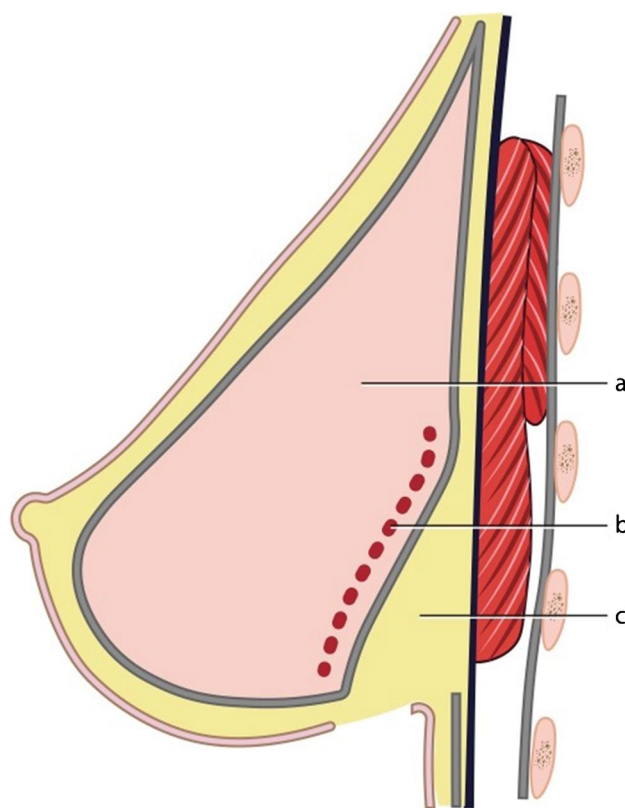


Fig. 2 Method of tissue dissection under the gland (a) in order to create the dynamic 4D lodge. The dissection starts between the deep fascia (fascia pectoralis) and the deep layer of the superficial fascia (see Fig. 1c). The subfascial dissection in addition to multiple fasciotomies (b) softens the glandular basis in order to create sufficient space in the subglandular pocket (c)

- The subcutaneous tissue is sharply incised down to the deep pectoral fascia. Then, the dissection extends between the deep fascia (fascia pectoralis) and the deep layer of the superficial glandular fascia (Fig. 2). The dissection ends above the nipple areola complex in order to free the lower portion of the major pectoralis muscle of the glandular body.
- Dissection of the submuscular pocket at the lower border of the major pectoralis muscle. Below this incision, the deep thoraco-abdominal fascia at its original junction with the superficial glandular fascia is preserved for later anchoring of the glandular superficial fascia (Fig. 2).
- The lower medial costal and sternal origin of the major pectoralis muscle is incised in order to gain muscular slack at its lower border but maintaining enough insertion in the upper-medial portion in order to prevent synmastia.
- The inferior detachment of the gland from the deep pectoralis fascia together with release of the medio-caudal pectoralis major muscle and submuscular pocket dissection generates a mobile composite tissue block that allows for ample space to take up the implant (Fig. 3c)

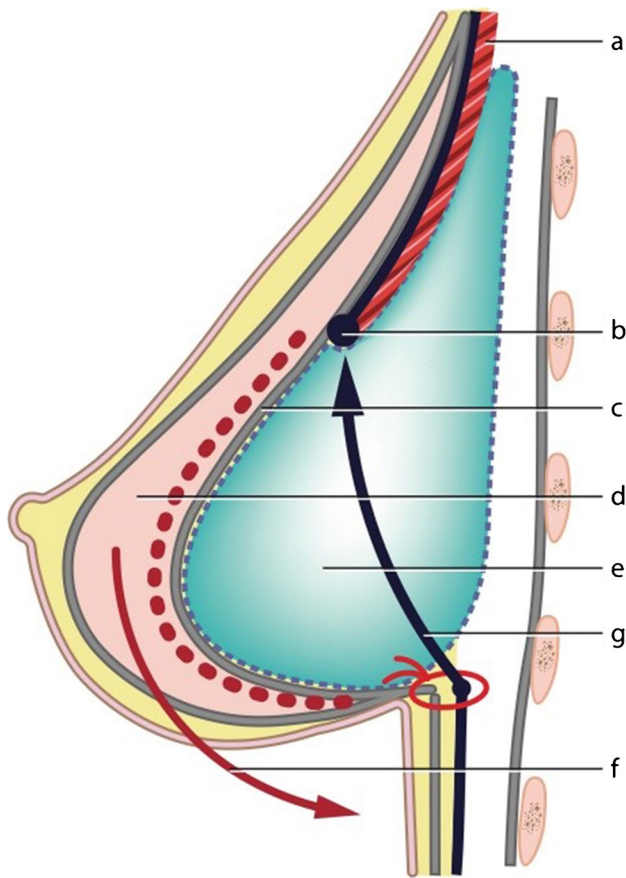


Fig. 3 Insertion of the implant into the 4D lodge. The implant lies behind the superiorly shifted muscle and the mobilized breast gland. The deep fascia has been incised to allow the released pectoralis muscle to slip cranially (a). The cranial margin of the incised deep fascia is firmly attached to the pectoralis muscle (b). The deep layer of the fascia (c) and the released gland (d) smoothly cover the implant (e) and allow to translocate the caudal border of the gland towards the deep fascia for fixation (f). The black arrow shows the significant upward movement of the detached major pectoralis muscle (g). A firm suture secures the glandular fascia to the superficial and the deep layer of the superficial glandular fascia (a) and to the deep fascia (red knot)

and [video](#)). This particularly tissue-saving type of pocket preparation spares most vessels from the pectoralis major muscle into the gland and creates permanently pressure change and tension conditions. This prevents the gland from atrophying due to a lack of perfusion.

- A key element of further dissection creating the proposed 4D pocket consists of fasciotomy. The original rigid fascia system that anatomically is designed to provide maximum attachment of the gland to the thoracic wall prevents a smooth wrapping of the implant. Therefore, it is incised horizontally and vertically in order to provide enough expansion over the implant (Fig. 3). By this maneuver, even high volume breast implants can be covered without problems. This final step has to be

performed meticulously in order to provide a maximum breast implant-to-gland contact and smoothen out any irregularities. By this the expanded gland can also be more easily mobilized down to the deepened inframammary fold. This procedure is also well suited to modify additional glandular deficits at the lower pole such as in grade I or II tubular breast deformity.

Fasciotomy was performed in all cases and its extent varied depending on the individual case. Fasciotomy has two goals:

1. To reduce tension of the mammary gland fascia in order to allow for breast tissue expansion over the implant.
2. To avoid muscle animation over the implant. It is critical in our opinion to perform fasciotomy of the caudal part at the lower border of the major pectoralis muscle even in small implant volumes. The extent of the fasciotomy correlated with the implant size in particular in the lateral lower pole.

- Sizers are inserted for definite decision on the implant position and size.
- The implant is inserted into the new multiplanar composite space and carefully oriented in case of anatomical implants.
- Suction drains (size 10) are inserted on either side.
- A long lasting stability of the inframammary fold is achieved through anchoring sutures of the glandular fascia to the superficial thoraco-abdominal fascia. This provides a strong barrier against dropping/bottoming out. We have seen only 4 cases in which the implant moved downwards due to a weak anchoring which accounts for a rate of 0.45% of bottoming out. Details of the technique that entails a fascial suture line of at least 6–8 cm are given in the [video](#).

A 3-layer wound closure is used. First, the superficial fascia is attached to the thoraco-abdominal deep fascia with 5 simple interrupted sutures (2–0 resorbable monofil) in doubling the fascia, thus preventing caudal slippage of the implant. Then, corium interrupted sutures (4–0-resorbable monofil) are applied followed by running intracutaneous suture (5–0 resorbable monofil) (Fig. 3). The creation of a stable inframammary fold effectively prevents “dropping-out” of the implant and lowering of the inframammary fold.

The lodge has a dynamic interaction with the implant due to the excursions of the overlying released gland (Fig. 3).

- Incision tape is placed and a bra is formed of gauze and tapes.

- Drains are removed 12–24 h after the surgery.

Follow-up

Sports and intense physical activity are prohibited for 6–8 weeks. During that time, a firm sports bra is worn. However, patients are encouraged to start careful early motion in order to maintain this highly mobile interface.

Patients were followed up between 3 and 22 years, with a mean of 6.5 years. All patients were examined after 3, 6, and 12 months postoperatively.

After that, the patients were encouraged to show up for an annual checkup.

Selection of implants

The following breast implant types were used:

- Anatomical shape Allergan/Natrelle 410 MM (65% of pts.), MF (34% of pts) and MX (0.5%)
- Mentor Contour Profile gel implants 300 Series, CPG 321 (24%), CPG 322 (75%), and CPG 323 (1%)
- Round SILTEX gel implants moderate-plus profile Xtra (50%) and Motiva Ergonomix demi/full (50%)

Due to a sporadic incidence of “double-capsule formation” and “late seroma” (12 patients, 1.37%), we switched to Mentor implants and finally in 2017 to Motiva. In 2018 and 2019, 90% of the implants implanted were Motiva Ergonomix Demi/Full und 10% Mentor Siltex Xtra.

Criteria for the choice of implants were anatomical pre-condition of the patient (shape, asymmetry, size) and quality of the soft tissue.

In patients with tubular deformity or a hypoplastic lower breast pole, anatomical implants were chosen. In skinny patients or those with atrophic tissue, Motiva ergonomix implants were used because of their softness and adaptation to the surrounding tissue and moving breast.

Long-term results

A subset of 33 patients was further analyzed for long-term results. Age at breast augmentation in this group was 27.5 ± 7.3 (19–45) years. The mean implant volume in these patients was 389 ± 56 (295–525) cc. The follow-up period in this group was 3 ± 2.1 years (0.4–9 years). In these patients with well-documented postoperative findings, measurements for sternal notch to nipple (SN-N), nipple to inframammary fold (N-IMF), nipple to midline (N-ML), and midclavicle to nipple (MC-N) were taken and put in relation to the preoperative findings in each patient.

Statistical analysis

The data was statistically evaluated using GraphPad prism 8 (San Diego, USA).

Continuous data were described with mean value, minimum and maximum (range). Categorical data were described with frequencies and percentages. Results are expressed as mean \pm SD. *N* numbers indicate results per patient if not otherwise indicated. For comparison of multiple experimental groups, one-way ANOVA was performed where indicated. Tukey’s multiple comparison post test was conducted after performing multiple comparison with ANOVA.

Results

Dissection of a dynamic implant pocket

The fascia on the posterior surface of the gland has been incised vertically and if needed horizontally to provide a smooth gliding plane over the implant together with the cranially attached muscle. The lowered muscle tension after release matches the elasticity of the incised posterior fascia.

Reliability of the anchoring sutures

A long lasting stability of the inframammary fold is achieved through anchoring sutures of the glandular fascia to the superficial thoraco-abdominal fascia. This provides a strong barrier against dropping/bottoming out. We have seen only 4 cases in which the implant moved downwards due to a weak anchoring which accounts for a rate of 0.45% of bottoming out. Details of the technique that entails a fascial suture line of at least 6–8 cm are given in the [video](#).

Long-term results

Examples for long-term results are given in Figs. 4 and 5. Noteworthy is the shape stability after breast feeding. The absence of unsightly muscle animation after 5 years can be depicted from Fig. 6. Also, the method proved to be valuable in revisional surgery of implant complications after subglandular (Fig. 7a) and submuscular implantation (Fig. 7b) leading to effective long-term prevention of massive capsular contracture even after more than 10 years. In patients with high tissue resistance and enough skin elasticity, long-term stability of the augmented breast can be observed even after multiple episodes of breast feeding

Fig. 4 Primary 4D augmentation in a 24-year-old patient with poor subcutaneous layer (**a**). Results after 4D augmentation at 1 year (**b**) and 5 years with breast feeding (**c**)

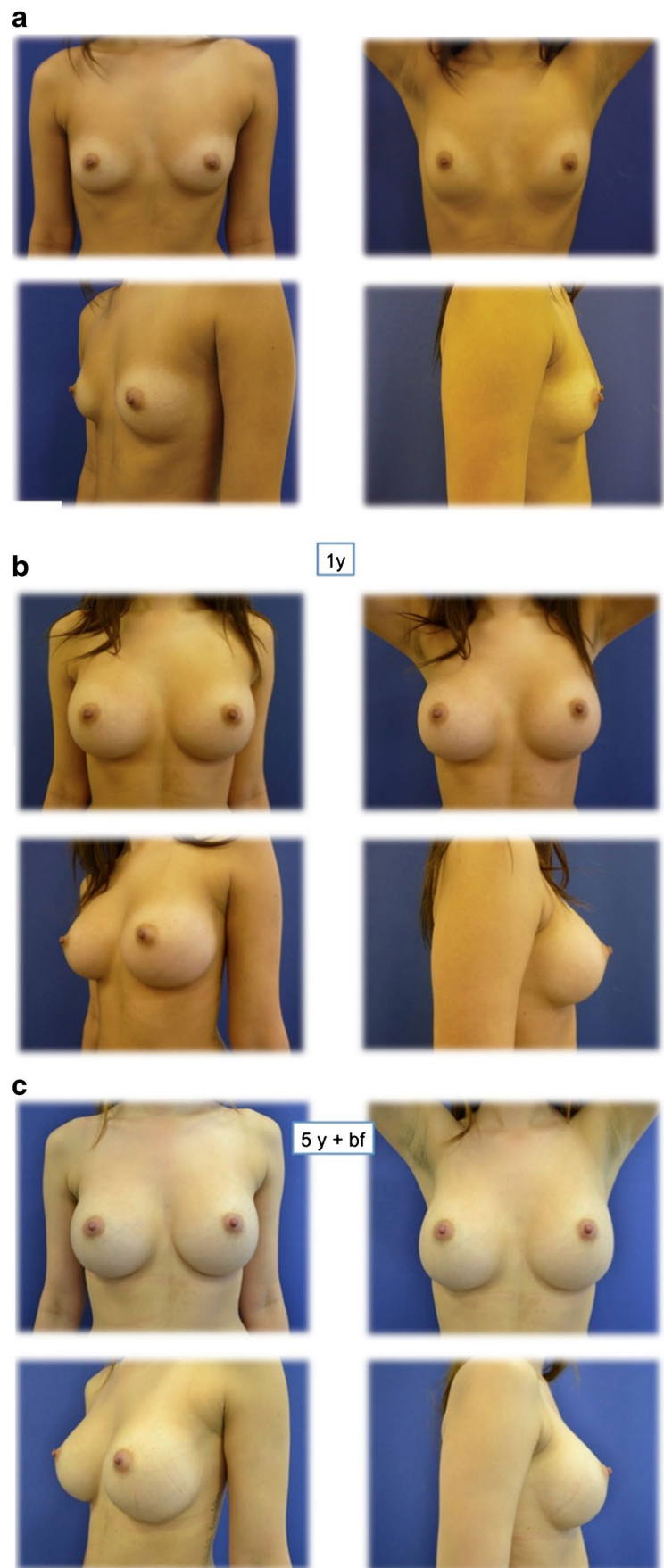
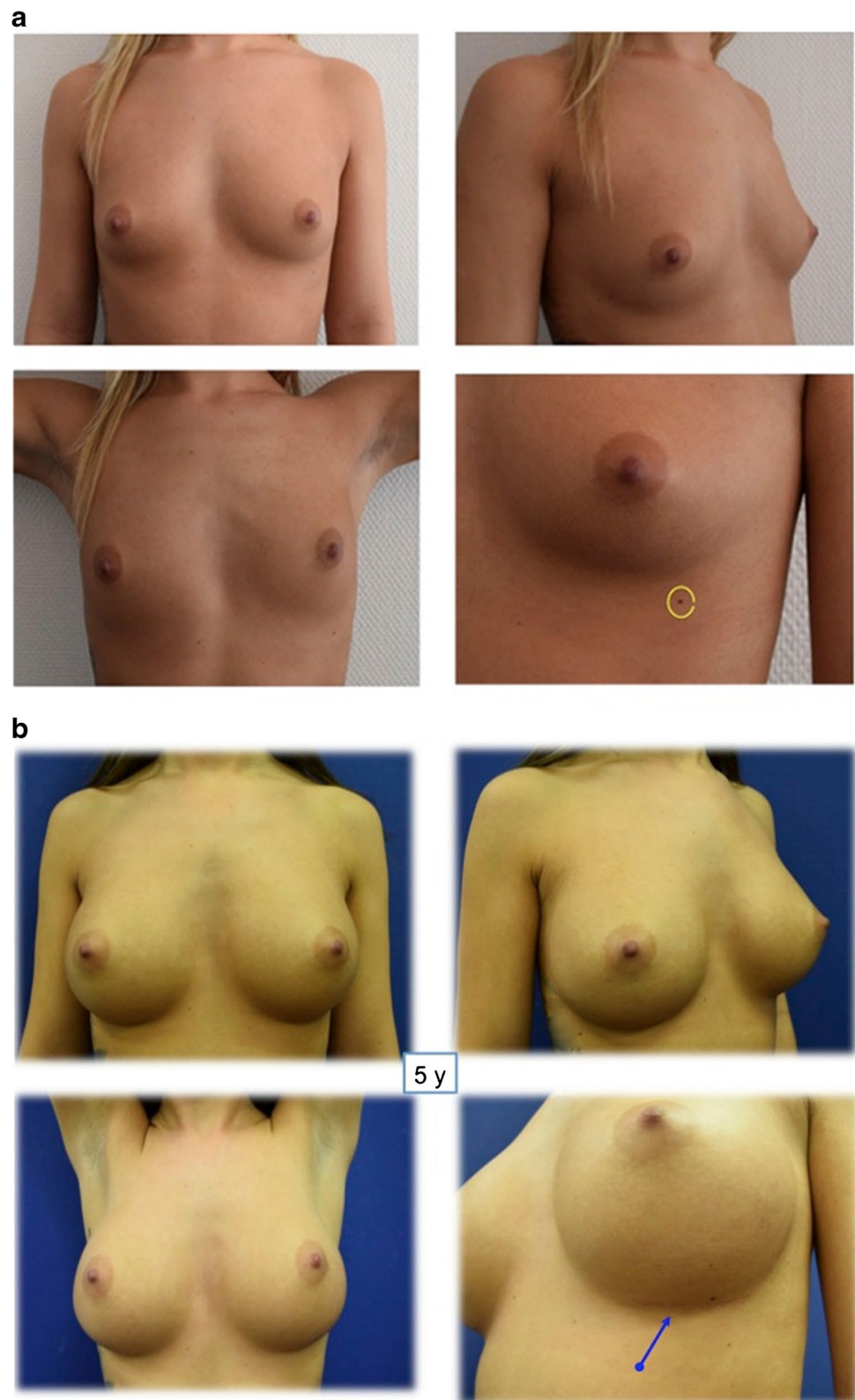


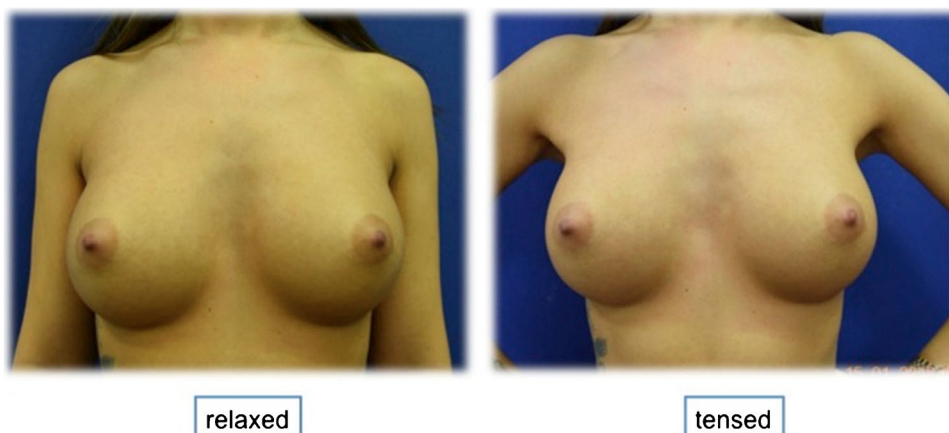
Fig. 5 Primary 4D augmentation with significant enlargement of the natural breast footprint in a 22-year-old patient (**a**). The effect of lowering the inframammary fold can be appreciated by the elevation of an abdominal nevus to the lower breast pole. The stability against a sagging lower pole is provided by stable anchoring the deep fascial layer to the thoracoabdominal fascia. Results after augmentation at 5 years (**b**). Arrow indicates cranial shifting of an inframammary nevus following implant insertion



(Fig. 8). The detailed analysis of the long-term follow-up patients is given in Fig. 9.

Measurements—taken at 3 months and 1, 2, 3, 5, and ≥ 7 years post augmentation—for SN-N, N-IMF, N-ML, and MC-N distances did not show any statistically

Fig. 6 Demonstration of absence of animation deformity when contracting the major pectoralis muscle (right)



significant changes over time. The achieved postoperative aspect is visualized in an overlay image of the patient (Fig. 10) and is due to the expansion of the adipo-glandular tissue with Cooper's ligaments over the implant in a fishnet-like structure that is generated by scoring of the posterior fascia (Fig. 11).

Complications

In the patient cohort of 867 patients, the overall complication rate was < 5%, including implant-related complications (capsular contraction and implant rotation). Revisions for bleeding were below 0.5%. Shape stability was observed over 7 years in more than 95% of the patients. In all patients (1734 implants), 18 implant defects were observed (0.1%). Allergan implants were exchanged to Motiva and Mentor respectively. In 15 patients (1.71%), double capsule formation had to be addressed, and in 5 cases (0.57%), a hematoma was evacuated. Early infections in 3 patients (0.3%) were treated by immediate intervention with revision, irrigation, and debridement. After 24 h, a second look operation was performed with reinsertion of a fresh implant.

Problems related to muscle release, such as shoulder instability, were not observed. In 2 patients carrying Allergan implants (0.2%), a painful late seroma was treated by implant exchange after capsulectomy and irrigation. No ALCL was diagnosed.

Complications observed were:

| | |
|--------------------------|------------------|
| Capsular fibrosis III/IV | (n = 8; 0.91%) |
| Double capsule/seroma | (n = 12; 1.37%) |
| Implant rotation | (n = 6; 0.68%) |
| Hematoma formation | (n = 1; 0.11359) |
| Double-bubble formation | (n = 2; 0.23%) |

Discussion

Implant-based breast augmentation is one the most performed aesthetic procedures and can be pleasing to both the patient and the surgeon.

This however requires that the aesthetic expectations concerning shape and sizes are met early and particularly long term. With increasing demands on the optimal result of implant-based breast augmentation, the skills and the armamentarium of any plastic surgeon are challenged. No longer a simple implantation but an immediate and long-term best possible result based on the individual anatomical prerequisites is warranted.

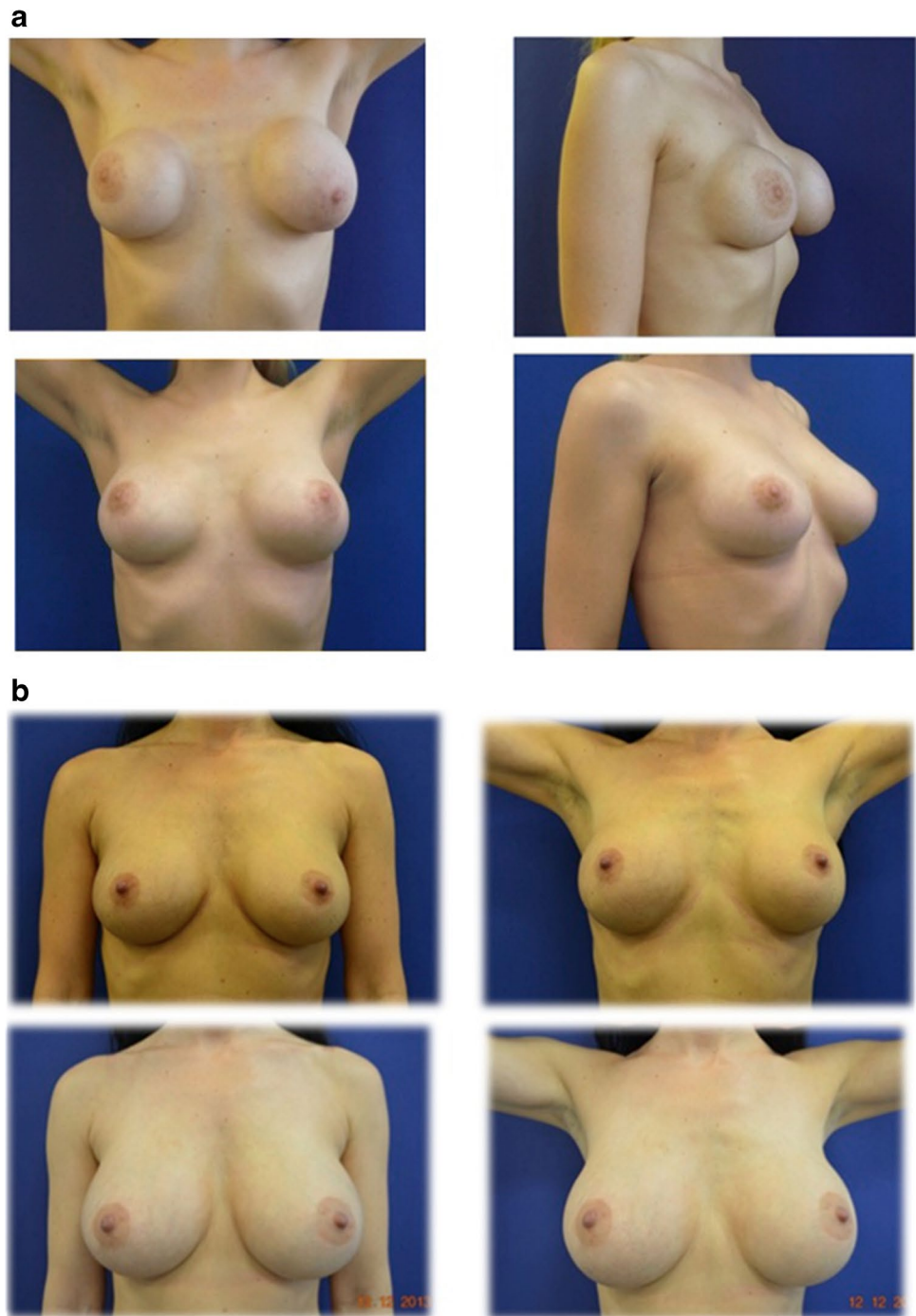
In particular in the long run, sustained stability, softness, and natural appearance are to be achieved.

The progress of implant technology, techniques of insertion, and additional procedures provides a wide range of options. However, the positioning of breast implants, scars related to the approach, and in particular the plane of insertion is an ongoing controversy in plastic surgery [6–9].

Recognizing that the plane of insertion of an implant has different pros and cons, the worldwide community of aesthetic surgeons advocates both the subglandular and submuscular approach. As introduced by Cronin [1], insertion of the implant in a subglandular epipectoral position has the advantage of ease and a primarily superior result at the price of a higher incidence of capsular contraction. Dempsey and Latham pioneered subpectoral implantation which showed the significant advantages of lower rates of capsular contraction, better infection resistance, preservation of nipple sensation, and improved breast contour [2].

Tebbetts later advocated the principle of “dual plane breast augmentation” creating an altered parenchyma–muscle interface thereby minimizing typical complications such as the double bubble phenomenon. He preserved the medial pectoralis muscle and lower origins in order to avoid

Fig. 7 Effects of the 4D technique in revision breast augmentation plasty. **a** This 33-year-old patient is suffering from deformation and 3rd degree capsular contracture after subglandular augmentation (upper row). Natural shape and dynamics after capsulectomy and implantation of larger anatomic implants in the 4D lodge (lower row). **b** This 35-year-old patient requested larger implants after previous biplanar breast augmentation (upper row). After intracapsular implant removal, the patient received implantation of anatomic implants in the submuscular 4D lodge. Note the potential of muscle release at the lower and medial origin and the effects of the expansion of the lower pole through incisions of the deep fascia giving way for the larger implants. Results after 11 years (lower row)



protrusion of the implant and synmastia. In his technique, the muscle must be divided to lower the inframammary fold. The strongest argument for this technique is that dual-plane augmentation mammoplasty adjusts implant and tissue relationships in order to optimize implant–soft tissue dynamics in a wide range of breast types [10].

A purely subfascial approach as suggested by R. Graf was considered to provide better implant coverage than the subglandular route by avoiding the dissection of the

pectoralis muscle. The authors arguments in favor of a subfascial plane was an avoidance of implant deformation or distortion leaving additional soft tissue between the implant and the skin, and minimizing implant edge prominence such as in strict retroglandular placement. Fewer patient complaints were seen while morbidity was found to be similar to other techniques [4]. It has become however clear from multiple publications that the rate of capsular contraction is definitely minimized when implants are covered by the

Fig. 8 In this 35-year-old patient, high tissue resistance and good tissue elasticity (**a**) allowed for significant augmentation (**b**). After 10 years and three pregnancies with breast feeding, the breast shape and stability has been sustained (**c**)

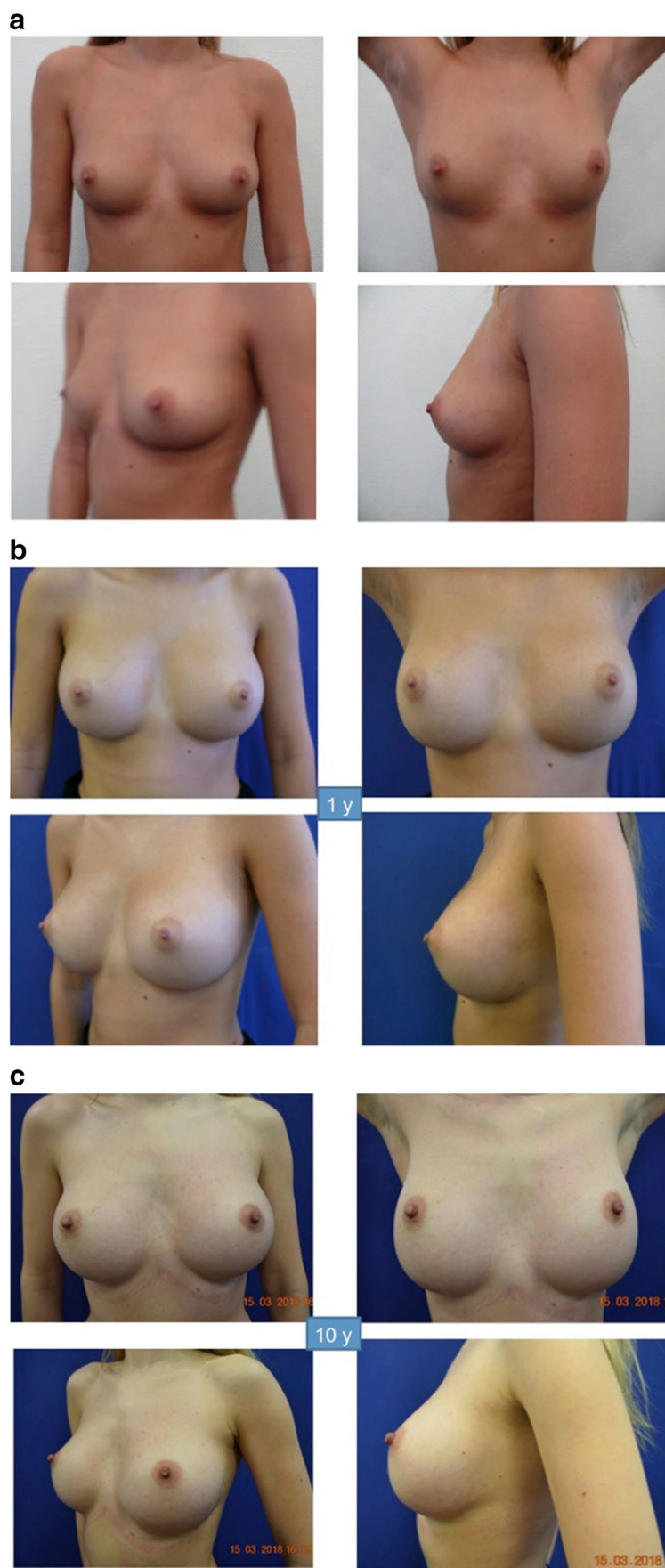
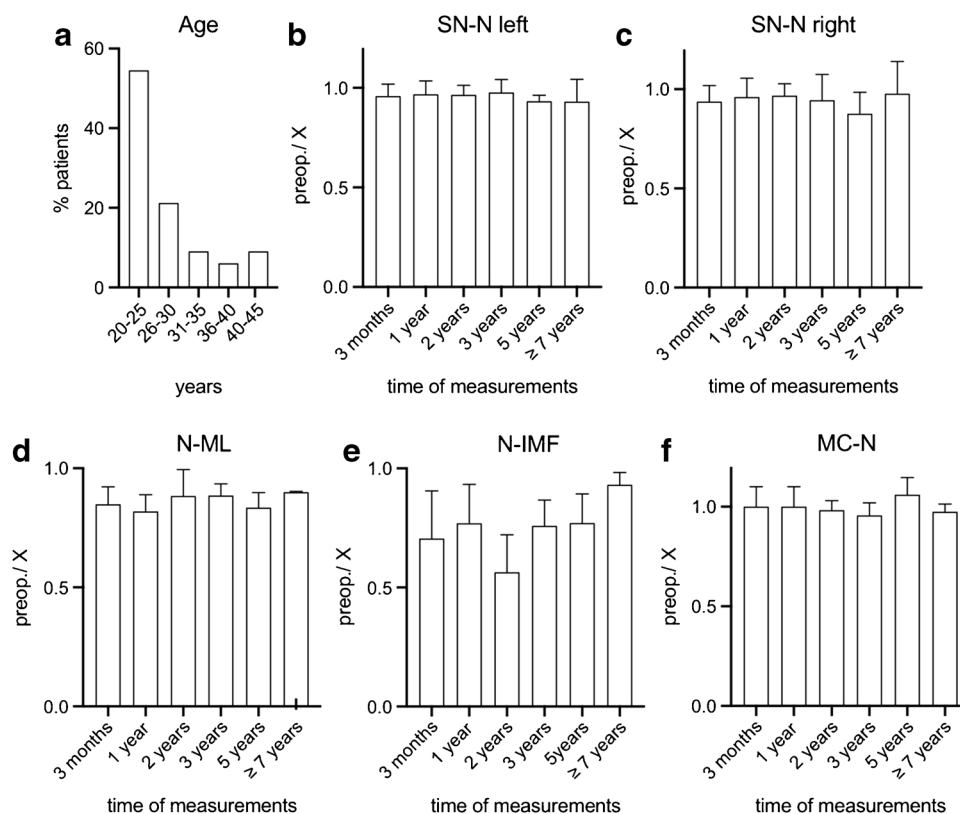


Fig. 9 Patient data for 33 women analyzed for long-term results after breast augmentation. No statistically significant differences were observed between the groups at the different time intervals of 3 months, 1 year, 3 years, 5 years, and more than 7 years after breast augmentation. Age distribution of patients is given in **a**. Measurements of sternal notch to nipple (SN-N) (**b**, **c**), nipple to median line (N-ML) (**d**), nipple to inframammary fold (N-IMF) (**e**) and midclavicle to nipple (MC-N) (**f**) are given as the quotient preop./postop. at different intervals. The obvious increase of the N-IMF postoperatively can be appreciated, but all the other parameters are not statistically significant in either of the groups in the different time intervals after operation. Altogether the N-IMF does not statistically significantly increase over time indicating the stability of the IMF fixation as well as the glandular tissue



pectoralis muscle [11]. Surgeons experienced in either of these techniques are constantly challenged by the fact that predictable and constant long-term results without capsular contracture cannot be achieved in all patients by all methods. One of the downsides in submuscular implantation is unnatural animation deformity that may range between minimal distortion in 62.5%, moderate distortion in 10%, and severe distortion in 5% [6]. While many of the unwanted aesthetic complications are unavoidable, others have to be ascribed to

mistakes such as insufficient definition of shape, insufficient analysis of soft tissue, inadequate size and shape of implants, irreparable destruction of ligamentous suspension and vascularization, inadequate fixation of the inframammary fold, and a too short dynamic healing phase.

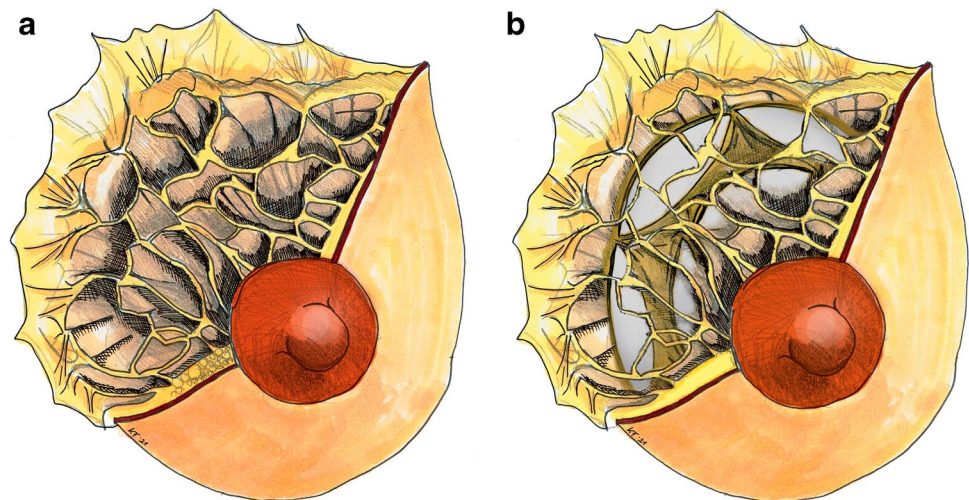
A logical approach therefore would be to combine the advantages of either of the established methods in one approach in order to avoid the most striking negative long-term consequences of breast implants such as capsular contracture, insufficient shape and volume, and unnaturally animated breasts.

Besides the fact that capsular contracture can be managed by submuscular implantation as shown by numerous authors, insufficient breast shape and volume and animation can be effectively approached through retroglandular or subfascial placement in most cases [12]. Karabeg et al. have described a technique of generating a fasciocutaneous lower pole flap in the dual-plane technique instead of just using skin for closure. They named it therefore dual-plane subfascial. They proposed an indication especially in breasts with little upper and medial pinch volume [13]. This however does not solve the problem of animation when too little free gland covers the lower implant pole. The rigid retroglandular (deep) layer of the superficial glandular fascia in many cases prevents sufficient expansion even after freeing a glandular flap. Moreover, the natural vascular supply of the gland strongly depends on

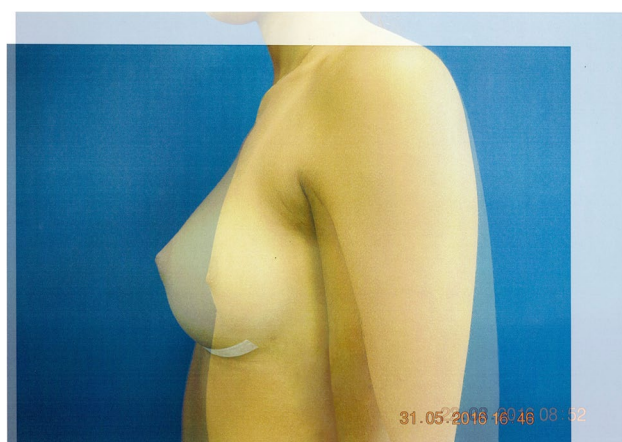

Fig. 10 The breast implant-induced increase of the N-IMF/LVC distance is visible in an overlay image of the patient

Fig. 11 The illustration shows the appearance fascial system of glandular tissue with Cooper's ligaments (a) joining in the fishnet-like stable structure after scoring over the implant (b). Fat tissue and glandular structures have been removed to show the fascial structures



the preexisting vascular network of the subdermal, preglandular, and subglandular plexus. Recent research indicates atrophy of breast parenchyma after subglandular, but not submuscular implantation. In contrast, submuscular breast augmentation caused atrophy of the pectoralis major muscle [14]. The preglandular and subglandular plexus supplies the parenchyma and the nipple-areola complex and complete dissection may significantly reduce gland perfusion. Strikingly retroglandular incisions play a significant role in modifying the shape in congenital breast deformities such as suggested by Puckett [15] and Sierra-Renom [16]. In the authors' opinion, augmentation of the specific pre-existing breast volume requires that the interaction of the implant in a retromuscular or retroglandular position with the local glandular tissue has to be specifically addressed.

In most of the augmentations adding significant implant volume, a distalization of the IMF is necessary in order to balance the breast by a proper increase of the low ventral curvature (LVC).

This means that the surgeon has to release the original IMF thereby increasing the distance between the nipple areola complex and the IMF. This however requires a stable anchoring of the IMF afterwards. In our technique, this is facilitated by placing firm sutures between the superficial fascia and deep fascia at the level of the newly defined IMF. This stable fixation between the fascial sheets prevents IMF violation and bottoming out.

Thereby a bottoming out of the implant behind the new IMF due to the consequences of violation of an IMF can be prevented. The sagging of an implant over a stable IMF which is commonly defined as ptosis is overcome by the hammock like stable adipo-fascio-glandular tissue at the lower ventral curvature. The space can be increased by scoring of the superficial glandular fascia. In our experience, this does not weaken the hammock like function due to the

fishnet-like structure of the strong Cooper's ligaments within the breast tissue.

In the standard submuscular augmentation, an unnatural move or even frozen aspect together with muscular animations may lead to an unfavorable result due to the rigid fascia. This results from the fact that the gland cannot be smoothly lifted due to tension in the distal muscular border and the jigsaw blade pattern of the suspensory ligaments. Some authors favor the periareolar approach in order to preserve the deep ligamentous attachments in the inframammary fold [17]. This approach however prevents any further refinements of the lower breast pole, which may be necessary to adapt the breast tissue to large implant sizes and shape the lower pole.

We found that the mobilized part of the inferior portions of the breast gland and its surrounding adipose tissue contributes significantly to the natural appearance of the breast. Historically its role in augmentation has been mainly addressed in the subglandular and subfascial approach while being more or less neglected in the standard submuscular pocket dissection. The gland in its anatomical integrity surrounded by the superfascial envelope and transected by the suspending ligaments is simply too stiff after simple epimuscular mobilization in order to give way sufficiently to the shaping effects of an implant.

Vegas and del Yerro put a lot of effort into examining the supportive quality of the soft tissue covering the anterior chest wall, in particular the fascias, Cooper's susp. ligaments, and the retinaculas. They focused on measurements comparing Young's elastic modulus to determine the supportive role of these closely networked structures. Their findings did confirm the initial requirements we met to develop the additional steps of the 4-D pocket. The determination of Young's elastic modulus for the pectoralis fascia with 100–2000 kPa and Cooper's susp. Lig with 80,000–400,000 kPa in comparison to gland with 7.5–66 kPa and the adipose tissue with 0.5–25 kPa, shows

that the sheathing of the implants is achieved by tissues with proven high elastic modulus [18]. Rehnke et al. have further explored the fascial system of the breast on the basis of Sir Ashley Cooper's work [19].

Despite various studies on the fascial system, the complex three-dimensional fascial system in the breast is not well understood. These authors set out to discover and describe a theory of superficial fascial structures responsible for breast shape. According to their anatomical studies, the superficial fascia system that surrounds the breast parenchyma and its attachments to the chest are found to comprise of a three-dimensional, closed system of fascia and fat surrounding the corpus mammae, which attaches to the skin by means of specialized vertical cutaneous ligaments, or Cooper's ligaments, and which attaches to the chest wall by means of a three-dimensional zone of adherence at the breast's periphery. As the breast is shaped by a three-dimensional, fibrofatty fascial system, two layers of this system surround the corpus mammae and fuse together around it, and anchor it to the chest wall in a structure what the authors called the circummammary ligament [19]. By dissection of the deep layer of the superficial fascia and scoring, we open up a space that allows the implant to lift and expand the breast tissue. The firm attachment by the circummammary ligament is maintained in the superior part and scored in the inferior part. At wound closure that fixes the posterior lamella firmly as the deepest suture layer to the thoraco-abdominal fascia deeply, the integrity of the inferior fascial support is achieved.

We have therefore further developed the dual-plane technique by adding a significant subfascial dissection of the mammary gland. This implies a rigorous release of the pectoralis origin and additional incisions of the deep layer of the superficial glandular fascia and the deep fascia attached to the major pectoralis muscle surface in order to interrupt the animation. The individual orientation of horizontal and vertical incisions allows for a precise definition of glandular expansion by the latter implant.

Moreover, by this technique, the definition of the lower breast pole and inframammary fold is no longer left to the natural course of tissue sagging over time alone but is controlled by an immediate release of the glandular deep fascial plane and definite anchoring of this fascial layer to the thoracoabdominal fascia. The data analysis supports the concept by measurable long-term stability of the N-IMF distance. Our technique is more than only a plane III dissection with glandular scoring, as there are additional steps involved. These steps have so far not been described in their rationale and extension. The technique does not aim to score the breast gland alone but to add dynamic features to the rigid superficial fascia that serves as an inner lining of the lower ventral curvature and carries the load of the implant in a dynamic fashion. This is of utmost importance as the expanded skin of the lower

ventral curvature (LVC) has to be protected from an overstretching by creation of an inner bra. In the area of the lower ventral curvature, this is provided by the superficial fascia covered by the superficial adipose tissue (SAT), in which the mammary gland is embedded. Any breast augmentation leads to an extension of the LVC, and therefore, a stability of the inner structures is necessary in order to preserve shape stability. The corresponding dynamic features of the stable superficial fascia are provided by multiple horizontal and vertical incisions (fasciotomies) reaching medially from the parasternal border to the lateral border of the lodge. These incisions lead to an increase of the inner fascial surface while preserving enough rigidity to retain the implant while allowing it to fill up the new space.

As an important additional step, vertical incisions at the lower border of the fascia profunda and the pectoralis major muscle are added. They are critical in avoiding animation deformities generated by the PMM. We are convinced by the clinical reproducibility that the deformity is not generated by the contracting muscle border but rather by the rigid band of the deep fascia pressing against the thoracic wall thereby generating an unpleasant ventral trough deformity.

Fasciotomies at the muscle border create open wedges that reduce the tension during muscle contraction and prevent the formation of the trough.

The way the lodge is generated facilitates a dynamic interaction between the implant and surrounding tissues and provides an obvious natural mobility of soft tissues including gland and implant. Interestingly the implant pocket provides both stability and a low rate of capsular fibrosis.

Textured implants per se do not grow in firmly to grant stability. They may stay mobile, rotate, and generate a fibrotic capsule. Therefore, shape stability as it was observed does not depend on the implant shell itself but on the absence of capsular fibrosis, proper implant fit in the lodge and dynamic interaction with the implant.

The type of implants did not play a role in form stability. Therefore, also the use of smooth (Motiva) implants was not followed by undesirable expansion of the LVC during the observed time period.

The strong and long lasting fixation to the remaining thoracoabdominal structures of the superficial and deep thoracoabdominal fascia gives enough control also for large implants exceeding the preoperative footprint of the gland which has been shown previously for corrective indications [20]. As we rely on the fixation of the circular band of the breast base fascial system to the superficial thoracoabdominal fascia, a long lasting stability of the inframammary fold is achieved through anchoring sutures of the glandular fascia to the superficial thoraco-abdominal fascia. This provides a strong barrier against dropping/bottoming out. We have seen only 4 cases in which the implant moved downwards due

to a weak anchoring which accounts for a rate of 0.45% of bottoming out. Details of the technique that entails a fascial suture line of at least 6–8 cm are given in the [video](#).

A 3-layer wound closure is used. First, the superficial fascia is attached to the thoraco-abdominal deep fascia with 5 simple interrupted sutures (2–0 resorbable monofil) in doubling the fascia, thus preventing caudal slippage of the implant. Then, corium interrupted sutures (4–0-resorbable monofil) are applied followed by running intracutaneous suture (5–0 resorbable monofil). The creation of a stable inframammary fold effectively prevents “dropping-out” of the implant and lowering of the inframammary fold. Beekman et al. [21] have successfully employed their own modifications of securing the inframammary fold, closing the pocket with interrupted Vycril 3.0 sutures. When lowering the IMF, sutures are fixed to the thoracic wall fascia. After interrupted subdermal sutures Vycril 4.0, final skin closure is performed with Monocryl 4.0.

Xu and Pu [22] suggest to close the incision in a 3-layered fashion: A 3–0 PDS (polydioxanone) (Ethicon Inc., Somerville, NJ) suture is used to approximate breast tissue and superficial fascia, followed by 3–0 Monocryl (Ethicon Inc.) for subdermal, and 4–0 Monocryl for subcuticular closure.

Modifications by Atiyeh [23] include the generation of a flap based on the cephalad skin flap and suturing this down to the fascia for more support or from the retroglandular plane while Ho et al. [24] employ a retromammary adipofascial flap. All these steps help to keep the IMF as the keystone of aesthetic breast augmentation in place.

In our experience, the remaining fascia together with the existing Coopers ligaments proved stable enough to resist the implant pressure even in slim patients. However, it is important to test the necessary remaining rigidity during the procedure and score the fascia accordingly. Even in skinny patients with small breasts (cup A size), large breast implants could be safely inserted due to the scoring of the fascia which was performed in a criss-cross fashion comparable to a mesh graft pattern.

In our experience, suturing—as described—leaves a stable inframammary fold as strong as the original fascial adherence.

Beyond the high level of control of an early size, shape, and inframammary fold definition, the augmented breast shows a lively appearance when the major pectoralis muscle is activated. This is mainly achieved by the creation of a highly mobile implant pocket that extends and stretches with the natural tissue movement along with the mobilized hypotensive lower muscle margin—the 4D pocket. The patient however has to be encouraged to mobilize this pocket early so as to adapt the mobilized and scored base of the mammary gland to the implant surface.

Stable shape and mobility under natural animation can be achieved by combining the best of all worlds of the existing

technical armamentarium in breast augmentation. Anatomically the 4D lodge is composed of a multiplanar soft tissue pocket in which the implant is partly located in a dynamic submuscular, subfascial, subcutaneous, and epithoracal position.

In our experience, this is the most natural implant location in relation to the overlying highly mobile original breast gland.

Supplementary Information The online version contains supplementary material available at <https://doi.org/10.1007/s00238-021-01816-2>.

Acknowledgements We thank Michaela von Aichberger (Figs. 1, 2 and 3) and Kai Fehler (Fig. 11.) for creating the technical illustrations. Also the assistance of Kai Fehler in image analysis is greatly appreciated.

Funding Open Access funding enabled and organized by Projekt DEAL.

Declarations

Ethical approval All procedures were in accordance with the ethical standards of the institutional research committee and with the 1964 Helsinki Declaration and its later amendments. This is an observational study. The Hannover Medical School Ethics Committee has confirmed that no ethical approval is required.

Informed consent Informed consent was obtained from all individual participants included in the study.

Patient consent Patients signed informed consent regarding publishing their data and photographs.

Conflict of interest Peter M. Vogt, Marian S. Mackowski, and Khaled Dastagir declare no conflict of interest.

Open Access This article is licensed under a Creative Commons Attribution 4.0 International License, which permits use, sharing, adaptation, distribution and reproduction in any medium or format, as long as you give appropriate credit to the original author(s) and the source, provide a link to the Creative Commons licence, and indicate if changes were made. The images or other third party material in this article are included in the article's Creative Commons licence, unless indicated otherwise in a credit line to the material. If material is not included in the article's Creative Commons licence and your intended use is not permitted by statutory regulation or exceeds the permitted use, you will need to obtain permission directly from the copyright holder. To view a copy of this licence, visit <http://creativecommons.org/licenses/by/4.0/>.

References

1. Cronin TD, Gerow FJ (1963) Augmentation mammoplasty: a new “natural feel” prosthesis. Transactions of the third international congress of plastic and reconstructive surgery, Washington. Excerpta Medica, Amsterdam, pp 41–49
2. Dempsey WC, Latham WD (1968) Subpectoral implants in augmentation mammoplasty Preliminary report. *Plast Reconstr Surg* 42:215

3. Tebbetts JB (2001) Dual plane breast augmentation: optimizing implant-soft-tissue relationships in a wide range of breast types. *Plast Reconstr Surg* 107(5):1255–1272
4. Graf RM, Bernardes A, Rippel R, Araujo LR, Damasio RC, Auersvald A (2003) Subfascial breast implant: a new procedure. *Plast Reconstr Surg* 111(2):904–908
5. Sampaio Goes JC (2010) Breast implant stability in the subfascial plane and the new shaped silicone gel breast implants. *Aesthetic Plast Surg* 34(1):23–28
6. Spear SL, Schwartz J, Dayan JH, Clemens MW (2009) Outcome assessment of breast distortion following submuscular breast augmentation. *Aesthetic Plast Surg* 33(1):44–48
7. Sun J, Mu D, Liu C, Ji K, Chen L, Liu W, Luan J (2016) Scar assessment after breast augmentation surgery with axillary incision versus inframammary fold incision: long-term follow-up in Chinese patients. *Aesthetic Plast Surg* 40(5):699–706
8. Munhoz AM, Gemperli R, Sampaio Goes JC (2015) Transaxillary subfascial augmentation mammoplasty with anatomic form-stable silicone implants. *Clin Plast Surg* 42(4):565–584
9. Pereira LH, Sterodimas A (2009) Transaxillary breast augmentation: a prospective comparison of subglandular, subfascial, and submuscular implant insertion. *Aesthetic Plast Surg* 33(5):752–759
10. Tebbetts JB (2006) Dual plane breast augmentation: optimizing implant-soft-tissue relationships in a wide range of breast types. *Plast Reconstr Surg* 118(7 Suppl):81S–98S; discussion 99S–102S
11. Egeberg A, Sorensen JA (2016) The impact of breast implant location on the risk of capsular contraction. *Ann Plast Surg* 77(2):255–259
12. Hunstad JP, Webb LS (2010) Subfascial breast augmentation: a comprehensive experience. *Aesthetic Plast Surg* 34(3):365–373
13. Karabeg R, Jakirlic M, Karabeg A, Crnogorac D, Aslani I (2019) The new method of pocket forming for breast implant placement in augmentation mammoplasty: dual plane subfascial. *Med Arch* 73(3):178–182
14. Roxo AC, Nahas FX, Salin R, de Castro CC, Aboudib JH, Marques RG (2016) Volumetric evaluation of the mammary gland and pectoralis major muscle following subglandular and submuscular breast augmentation. *Plast Reconstr Surg* 137(1):62–69
15. Puckett CL, Concannon MJ (1990) Augmenting the narrow-based breast: the unfurling technique to prevent the double-bubble deformity. *Aesthetic Plast Surg* 14(1):15–19
16. Serra-Renom JM, Munoz-Olmo J, Serra-Mestre JM (2011) Treatment of grade 3 tuberous breasts with Puckett's technique (modified) and fat grafting to correct the constricting ring. *Aesthetic Plast Surg* 35(5):773–781
17. Salgarello M, Visconti G (2017) Staying out of double-bubble and bottoming-out deformities in dual-plane breast augmentation: anatomical and clinical study. *Aesthetic Plast Surg* 41(5):999–1006
18. Vegas MR, Martin delYerro JL (2013) Stiffness, compliance, resilience, and creep deformation: understanding implant-soft tissue dynamics in the augmented breast: fundamentals based on materials science. *Aesth Plast Surg* 37:922–930
19. Rehnke RD, Groening RM, Van Buskirk ER, Clarke JM (2018) Anatomy of the superficial fascia system of the breast: a comprehensive theory of breast fascial anatomy. *Plast Reconstr Surg* 142:1135–1144
20. Wessels L, Murphy S, Merten S (2014) The capsular hammock flap for correction of breast implant ptosis. *Aesthetic Plast Surg* 38(2):354–357
21. Beekman WH, Beekman VK (2020) The breast implant ARC: an algorithm for determining the position of the IMF in breast augmentation planning. *Aesth Plast Surg* 44:16–23
22. Xue Y, Pu LLQ (2021) Contemporary breast augmentation in the US. *Ann Plast Surg* 86(3S Suppl 2):S177–S183. <https://doi.org/10.1097/SAP.0000000000002646>
23. Atiyeh B, Chahine MF (2016) Comments on “A four-layer-wound closure technique with barbed sutures for stable reset of the inframammary fold in breast augmentation.” *Aesthet Surg J* 36(9):NP291–NP292
24. Ho H, Kim KK, Lee KH, In-Beom K, Lee PK (2018) The use of a retromammary adipofascial flap in breast augmentation for patients with thin soft tissue. *Plast Surg* 42:1447–1456

Publisher's note Springer Nature remains neutral with regard to jurisdictional claims in published maps and institutional affiliations.